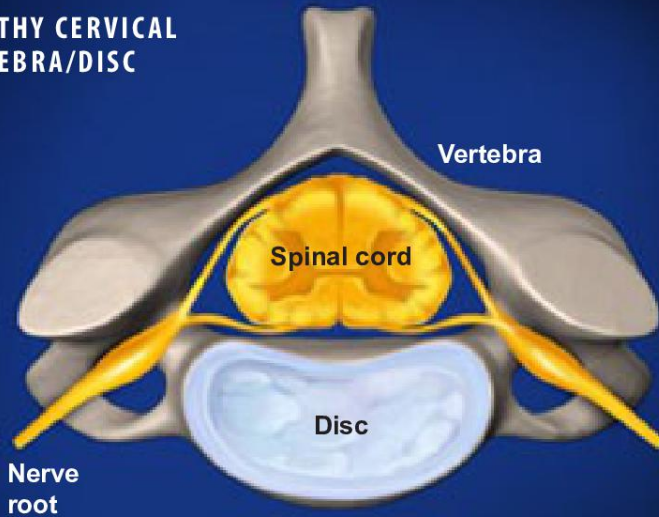




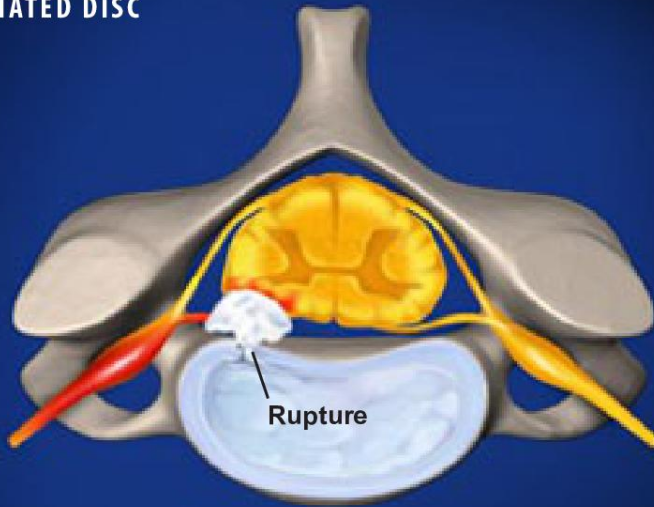
See the video

## Cervical Radiculopathy

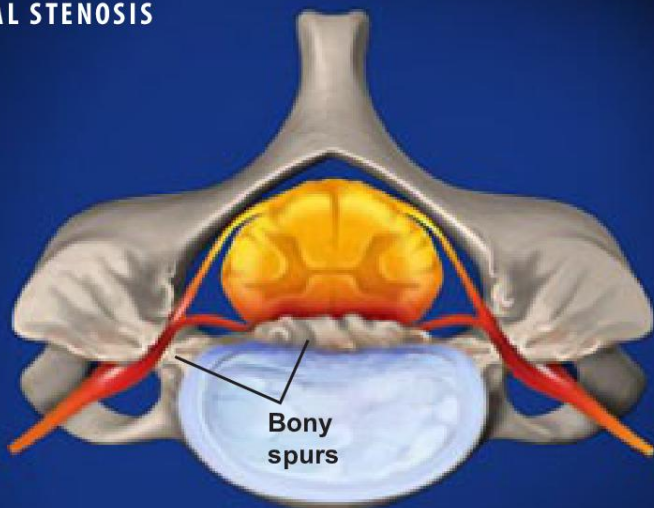
### HEALTHY CERVICAL VERTEBRA/DISC



### HERNIATED DISC



### SPINAL STENOSIS



### Overview

This condition is an irritation or compression of one or more nerve roots in the cervical spine. Because these nerves travel to the shoulders, arms and hands, an injury in the cervical spine can cause symptoms in these areas. Cervical radiculopathy may result from a variety of problems with the bones and tissues of the cervical spinal column.

### Causes (Herniated Disc)

One common cause is a herniated disc. A herniated disc is a rupture in the fibrous outer wall of a vertebral disc, which allows the soft nucleus of the disc to bulge outward. This bulge can press harmfully against a nerve root.

### Causes (Degenerative Disc Disease)

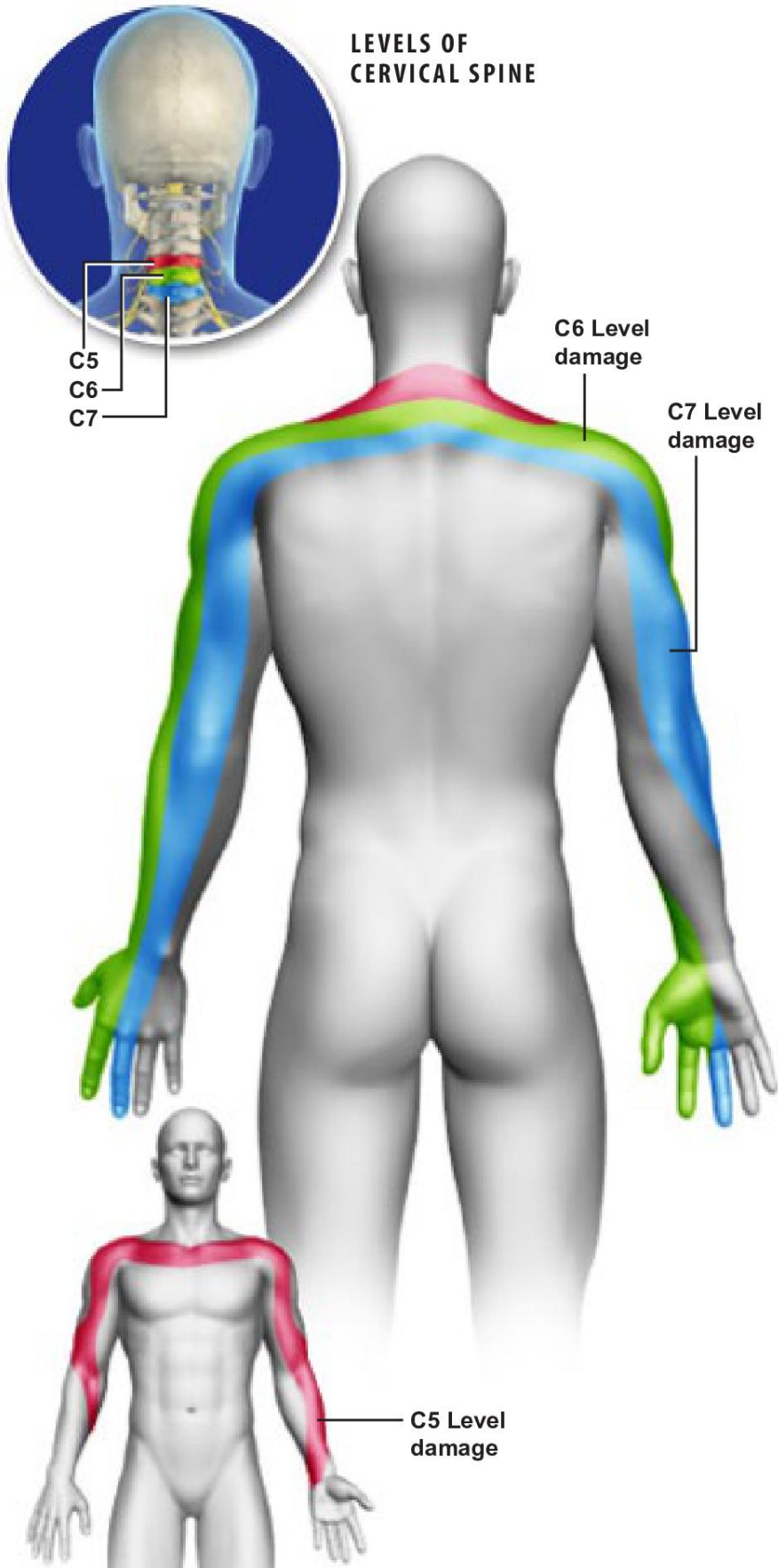
Another common cause of nerve root injury is degenerative disc disease. It occurs when a spinal disc weakens, allowing vertebral bones above and below the disc to shift out of position. The bones can touch, pinching nearby nerve roots.

### Causes (Spinal Stenosis)

When bones, discs or joints of the spine degenerate, bony spurs may form and push into the spinal canal or foramen space. This is called spinal stenosis, and it can also create harmful pressure against the spinal cord or nerve roots.



## Cervical Radiculopathy



### Symptoms

Nerve root injury in the cervical spine most commonly involves one of the three lowest levels of cervical vertebrae, which are called C5, C6 and C7. Symptoms may include pain, weakness, numbness and tingling, and may vary depending on the level of the injury. For example, an injury at the C5 level may cause pain and weakness in the shoulder and upper arm. An injury at the next vertebral level (the C6 vertebrae) may cause pain in the shoulder and the arm, and it may also cause weakness in the arm. And finally, an injury at the lowest level (the C7 vertebrae) may cause pain from the neck all the way down to the hand, along with weakness in the arm and hand.